



ARTICLE

Reduction in Lesion Incidence in Pork Carcass Using Transdermal Needle-free Injection of Foot-and-Mouth Disease Vaccine

Eun Young Ko^{1,2,†}, Jaesung Cho^{2,†}, Jin Ho Cho³, Kyung Jo², Seung Hwan Lee², Yoon Ji Chung², and Samooel Jung^{2,*}

¹Dodram Pig Farmers' Cooperative, Icheon 17405, Korea

²Division of Animal and Dairy Science, Chungnam National University, Daejeon 34134, Korea

³Department of Animal Science, Chungbuk National University, Cheongju 28644, Korea

OPEN ACCESS

Received September 13, 2018

Revised October 8, 2018

Accepted October 10, 2018

*Corresponding author : Samooel Jung
Division of Animal and Dairy Science,
Chungnam National University, Daejeon
34134, Korea
Tel: +82-42-821-5774
Fax: +82-42-825-9754
E-mail: samooel@cnu.ac.kr

*ORCID

Eun Young Ko
0000-0002-8686-1762
Jaesung Cho
0000-0002-9720-7950
Jin Ho Cho
0000-0001-7151-0778
Kyung Jo
0000-0002-3006-5396
Seung Hwan Lee
0000-0003-1508-4887
Yoon Ji Chung
0000-0002-6906-6468
Samooel Jung
0000-0002-8116-188X

† Eun Young Ko and Jaesung Cho contributed equally to this work and should be considered co-first authors.

Abstract Foot-and-mouth disease (FMD) is an infectious disease affecting pigs. The control of FMD in swine husbandry is very important because its outbreak results in a vast economic loss. FMD vaccination has effectively controlled FMD; however, it results in economic loss associated with the incidence of lesions in the pork meat at the injection site. The objective of this study was to investigate the effects of transdermal needle-free injection (NFI) of the FMD vaccine on the incidence of lesions at the injection site. Pigs (n=493) in the control group were vaccinated with the FMD vaccine using a commercial syringe needle, while 492 pigs in the transdermal NFI group received the FMD vaccine using a needle-free gas-powered jet injector. After the slaughter of the pigs, the incidence of lesions at the injection site of all pigs was checked by plant workers. The result of this study showed that the incidence of lesions in the pork ham from pigs vaccinated with NFI was 14.82% lower than that in control pigs ($p < 0.01$). In addition, lesions generated in the NFI group were found just in the subcutaneous tissue. Therefore, the incidence of lesions at the injection site in pork from pigs vaccinated with the FMD vaccine can be effectively reduced by using transdermal NFI rather than a conventional syringe needle.

Keywords foot-and-mouth disease vaccine, lesions, abnormal meat, needle-free injection

Introduction

Foot-and-mouth disease (FMD) is an infectious disease affecting pigs and other cloven-hoofed animals, and its outbreak results in a vast economic loss. Therefore, the control of FMD is very important in swine husbandry and is achieved via FMD vaccination (Ko et al., 2018). The intensive vaccination campaigns for FMD were started in 2011 in Korea because a large outbreak of FMD became a problem across the nation in 2010.

The vaccination is generally delivered with an injection because that has higher

absorptivity than oral inoculation (Li et al., 2011). However, the vaccine administered by a needle syringe results in adverse effects such as pain, stress, broken needle residue in the carcass, tissue damage, and incidence of lesions at the injection sites such as neck and ham (Chase et al., 2008). A previous study found lesions such as granuloma, abscess, and fibrosis at the vaccination site in animal carcasses (Ferreira et al., 2016; Yeruham et al., 2001). In addition, Ko et al. (2018) reported that the incidence of lesions in pork butt severely increased after FMD vaccination. The incidence of lesions in pork results in an economic loss in swine husbandry because the lesioned areas are discarded, and the surrounding areas are trimmed.

The tissue damage and bacterial contamination caused by syringe needles are a reason for the incidence of lesions in the injection site (Chase et al., 2008; Li et al., 2011). Therefore, needle-free injection (NFI) has been recommended in swine husbandry. NFI has many advantages compared to conventional injection methods using a syringe needle. It requires a low volume of vaccine and results in less pain, less stress, and no risk of residual needles in the pork carcass (Mitragotri, 2006; Sarno et al., 2000). In NFI, the vaccine penetrates the tissue by mechanical compression generated by a spring, battery, or gas in NFI (Chase et al., 2008). NFI is divided into two categories depending on the penetration depth of the vaccine with different compression force. NFI with a high compression force results in the penetration of the vaccine into the muscle tissue (intramuscular NFI). The vaccine can be deposited under the subcutaneous tissue by reducing the compression force (transdermal NFI). Previous studies have suggested that NFI of vaccines could reduce the incidence of lesions at the vaccination site of animals (Chase et al., 2008; Li et al., 2011). However, Ko et al. (2018) found no effect of intramuscular NFI on the incidence of lesions at the site of FMD vaccination.

Therefore, we investigated the effect of transdermal NFI of the FMD vaccine on lesion incidence at the injection site of pigs compared to conventional injection using a syringe needle.

Materials and Methods

Animals and treatments

A total of 983 growing pigs were raised in a farm (Hamyang-Gun, Korea) and were cared for in accordance with the guidelines of Dodram Pig Farmers' Cooperative. The piglets were vaccinated in the left ham twice at 56 d and 84 d of age with FMD O Compos (Aftogen Oleo[®], Biogenesis Bago Ltd., Argentina), which was emulsified with the adjuvant (Montanide ISA 50 V2 80%/V2 20%, water in oil). Pigs (n=493) in the control group were vaccinated using a commercial syringe with 2 mL of vaccine. In the transdermal NFI group, 0.5 mL of the vaccine was injected into pigs (n=492) using a gas-powered jet injector (Pulse 50, Tri-on international Co., Ltd., Seoul, Korea) following the guidelines of the manufacturer. Pigs were slaughtered between March 2018 and August 2018 at six different times with consideration of the market weight in the Dodram livestock processing complex slaughterhouse (Gimje-si, Korea). Eighty-two or eighty-three pigs per treatment were slaughtered at each time, and each slaughter time was considered as a replication.

Inspection of lesions at pork ham

The pork carcasses were deboned in the Dodram livestock processing complex (Gimje-si, Korea). The incidence of lesions such as abscesses, fibrosis, and granulomata in the pork ham of all carcasses was inspected by plant workers. The number of pork carcasses that had lesions in the pork ham was recorded.

Statistical analysis

This study examined the effect of transdermal NFI of the FMD vaccine on the incidence of lesions at pork ham by estimating the following linear model.

$$Y_i = \beta_0 + \beta_1 X_i + \beta_x Z_i + e_i$$

where Y_i is the incidence of lesions, X_i is NFI treatment, Z_i is the number of pigs, and e_i is the usual error term for the observation i , $e_i \sim N(0, \sigma^2)$. The number of pigs is included in the model to consider the potential effect of the difference in the number of pigs on the incidence of lesions. The models were estimated using Stata 14 software (StataCorp., 2015).

Results and Discussion

The adjusted coefficient of determination is 0.9543, which implies that the estimated regression explains the relationship between independent variables and dependent variable very well. The estimation result showed that transdermal NFI of the FMD vaccine into pigs had a statistically significant effect on the incidence of lesions in the pork ham (i.e., the vaccination site) at $p < 0.01$. The incidence of lesions in the pork ham from pigs vaccinated by transdermal NFI was 4.35% while that from control was 19.17% (Fig. 1). The use of transdermal NFI reduced the incidence of lesions by 14.82% compared to conventional injection with syringe needle. On the other hand, the effect of the number of pigs tested in this study on the incidence of lesions in pork ham was relatively small and not statistically significant. Since we used an ordinary least square method to estimate the linear model, variance inflation factors (VIF) for independent variables and the Breusch-Pagan test were conducted to detect multicollinearity and heteroscedasticity. The VIF for both treatments and number of pigs tested was 1.02 and the result of the Breusch-Pagan test was that $p > \chi^2 = 0.5850$. Therefore, neither multicollinearity nor heteroscedasticity was detected.

The incidence of lesions in the pork meat at the injection sites associated with the injection of various vaccines, including the FMD vaccine, has been reported (Houser et al., 2004; Ko et al., 2018; Vatulini et al., 2005). It is known that the tissue damage and contamination caused by a syringe needle and vaccine adjuvant are major factors in generating lesions (Li et al., 2011; Reurink et al., 2014). A previous study found that the intramuscular NFI of the FMD vaccine into pigs generated similar lesions to the injection of the FMD vaccine using a syringe needle at a pork butt injection site (Ko et al., 2018). However, the

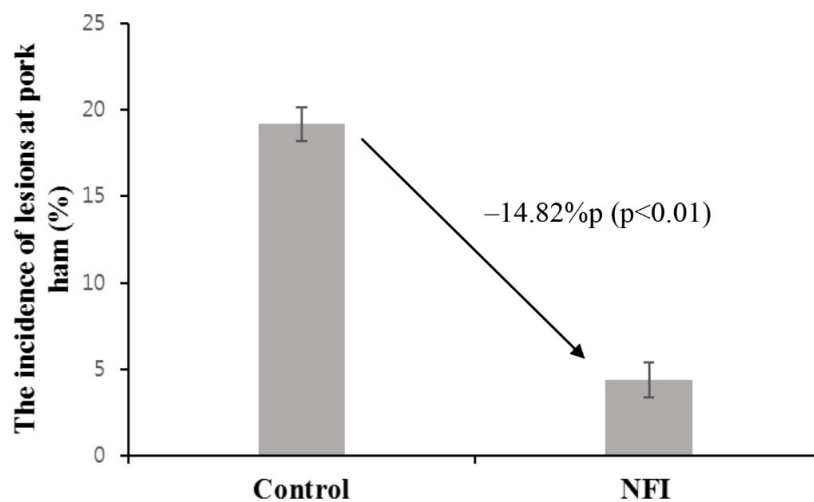
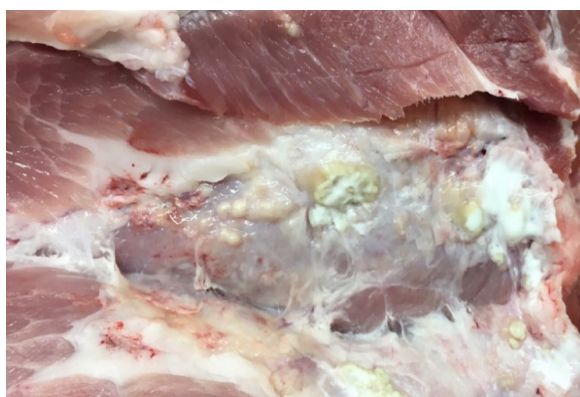

Fig. 1. The incidence of lesions at the pork ham injection site from pigs vaccinated with the FMD vaccine using a conventional syringe needle (control) or transdermal needle-free injection (NFI).

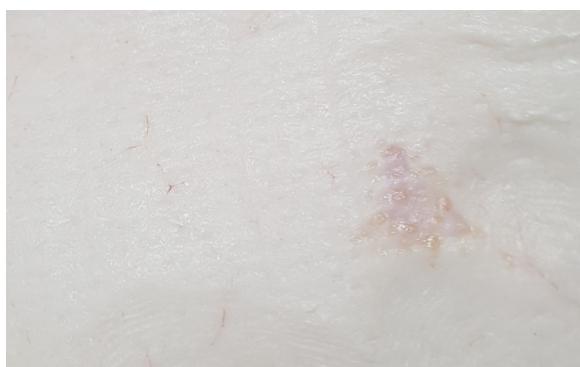
transdermal NFI of the FMD vaccine decreased the incidence of lesions in the pork ham effectively in the present study. The different effects between intramuscular NFI and transdermal NFI on the lesion incidence at the injection site of vaccines may be related with the deposited positions of vaccines. The intramuscular NFI of vaccines deposits vaccines in muscles that could generate lesions by the residue of vaccine adjuvant in muscle (Chase et al., 2008; Vatulini et al., 2005). However, the transdermal NFI of vaccines deposited vaccines between subcutaneous tissue and underlying shallow muscle. Therefore, the transdermal NFI of vaccines might not damage muscle tissue (Chase et al., 2008). The lesions in the pork ham were generated as in Fig. 2 when the FMD vaccine was injected using a syringe needle in the present study, which led to a five-dollar per affected pig deduction from a farm (data not shown). However, pigs that were vaccinated using transdermal NFI did not lead to a deduction because no lesions were found in the muscle of the pork ham. Although lesions were also generated in the pork ham of pigs vaccinated using transdermal NFI, the faint lesions were found only in subcutaneous tissue (Fig. 2).

The NFI of vaccines is known to enhance immune response because of the larger dispersion of vaccines compared with vaccination using a syringe needle which increases the reaction antigen-presenting cells to the antigen (Jackson et al., 2001). In addition, the transdermal NFI of vaccines is more effective in enhancing the immune response because the more antibodies are generated when the antigen is delivered to the dermal and subcutaneous tissues because those tissues have more antigen-presenting cells than muscle (Itano et al., 2003; Mitragotri, 2005).

The use of the NFI device in swine husbandry requires an additional cost for purchasing and maintaining the device. Nevertheless, the decrease in abnormal meat production caused by a reduced incidence of lesions in pork meat can be economical in the long term. In addition, needle-stick injuries in swine workers can be prevented with the use of the NFI device.



Control



NFI

Fig. 2. Lesions generated in the muscle (control) and subcutaneous tissue (NFI) of pork ham from pigs vaccinated with the FMD vaccine using a conventional syringe needle (control) or transdermal needle-free injection (NFI).

Conflicts of Interest

The authors declare no potential conflict of interest.

Acknowledgements

This work was carried out with the support of “Cooperative Research Program for Agriculture Science & Technology Development (Project No. PJ01206701)” Rural Development Administration, Republic of Korea. We also thanks to the farm that had played a part in this experiment.

References

- Chase CC, Daniels CS, Garcia R, Milward F, Nation T. 2008. Needle-free injection technology in swine: Progress toward vaccine efficacy and pork quality. *J Swine Health Prod* 16:254-261.
- Ferreira LC, Cooke RF, Marques RS, Fernandes HJ, Fernandes CE, Stelato R, Franco GL, Lemos RAA. 2016. Effects of vaccination against foot-and-mouth disease virus on reproductive performance of *Bos indicus* beef cows. *J Anim Sci* 94:401-405.
- Houser TA, Sebranek JG, Thacker, BJ, Baas TJ, Nilubol D, Thacker EL, Kruse F. 2004. Effectiveness of transdermal, needle-free injections for reducing pork carcass defects. *Meat Sci* 68:329-332.
- Itano AA, McSorley SJ, Reinhardt RL, Ehst BD, Ingulli E, Rudensky AY, Jenkins MK. 2003. Distinct dendritic cell populations sequentially present antigen to CD4 T cells and stimulate different aspects of cell-mediated immunity. *Immunity* 19:47-57.
- Jackson LA, Austin G, Chen RT, Stout R, DeStefano F, Gorse GJ, Newman FK, Yu O, Weniger BG, Vaccine Safety Datalink Study Group. 2001. Safety and immunogenicity of varying dosages of trivalent inactivated influenza vaccine administered by needle-free jet injectors. *Vaccine* 19:4703-4709.
- Ko EY, Jung S, Jeong HK, Han JH, Son JH. 2018. Effects of foot-and-mouth disease vaccination location and injection device on the incidence of site lesions in pork. *Korean J Food Sci An* 38:498-505.
- Li W, Yin Y, Wang F, Miao S. 2011. Beef quality assurance injection sites and techniques. *J Agric Sci* 4:91-96.
- Mitragotri S. 2005. Immunization without needles. *Nat Rev Immunol* 5:905-916.
- Mitragotri S. 2006. Current status and future prospects of needle-free liquid jet injectors. *Nat Rev Drug Discov* 5:543-548.
- Reurink G, Goudswaard GJ, Moen MH, Weir A, Verhaar JA, Tol JL. 2014. Myotoxicity of injections for acute muscle injuries: A systematic review. *Sports Med* 44: 943-956.
- Sarno MJ, Blase E, Galindo N, Ramirez R, Schirmer CL, Trujillo-Juarez DF. 2000. Clinical immunogenicity of measles, mumps and rubella vaccine delivered by the Injex jet injector: Comparison with standard syringe injection. *Pediatr Infect Dis J* 19:839-842.
- StataCorp. 2015. Stata statistical software. Release 14, StataCorp LP, College Station, TX, USA.
- Vatulini S, Macchi C, Ballanti P, Cherel Y, Laval A, Theaker JM, Bak M, Ferretti E, Morvan H. 2005. Aluminum hydroxide-induced granulomas in pigs. *Vaccine* 23:3999-4004.
- Yeruham I, Yain H, Haymovich M, Perl S. 2001. Adverse reactions to FMD vaccine. *Vet Dermatol* 12:197-201.